

## **Subfascial Breast Augmentation: Review of a 2-Year Experience with 100 Cases**

AHMED ALI, M.D.; EMAN ELEATHY, M.D.; SHERINE ABDO-FOTOUH, M.D. and  
MOHAMED FARAG, M.D.

*The Department of Plastic & Reconstructive Surgery, Faculty of Medicine, Ain Shams University, Cairo, Egypt.*

### **ABSTRACT**

This article presents a retrospective study of a 2-year experience with the subfascial plane of breast augmentation. This technique was employed to avoid the pitfalls of the popular subglandular and submuscular planes. The study included 100 patients underwent subfascial breast augmentation in four centers in two different centuries. Follow-up and analysis of the postoperative data showed that 89 patients (89%) were satisfied with the results. The reported complications were hematoma and asymmetry. The use of this technique can minimize the capsular contracture, bottoming-out and visibility of the edge of the implant which encountered with the subglandular plane. In the same time, it can gather the advantages of subglandular and submuscular planes. The study concluded that breast augmentation with the subfascial plane is an innovative technique and can replace the other planes for breast augmentation.

### **INTRODUCTION**

Breast augmentation is one of the most popular surgical cosmetic procedures. This is partially because of the increasing demand for better shape and partially due to the development of modern types of implants, and refinement in the surgical techniques [1,2]. The approach, the pocket plane, implant type and design as well as the tissue characteristics are contributing factors in a successful outcome.

The pocket plane plays an important role in the dynamics between the implant and soft tissue after breast augmentation. Cronin and Gerow introduced the subglandular pocket plane which is still the most commonly employed technique [3]. Capsular contracture, bottoming-out and visibility of the edge of the implant were the pitfalls of the subglandular plane [4-7]. The subpectoral and totally submuscular planes were introduced to overcome these pitfalls [8-12]. Despite the advantage of concealing the implant edges using these planes, im-

plant displacement occurred with contraction of the pectoralis muscle [13-16]. Tebbetts introduced the dual-plane technique that positions the implant partially behind the pectoralis muscle and partially in a retromammary location [17].

Graf and his colleagues introduced the subfascial plane and they reported good results that minimized the deficits of subglandular plane and has the advantages of the retropectoral plane [19]. On the next year two studies reported the advantages of the technique in terms of satisfactory breast shape and less fibrous capsular contracture [20,21]. This retrospective study was designed to evaluate the results of the subfascial plane of breast augmentation.

### **PATIENTS AND METHODS**

This retrospective study included 100 female patients that had undergone subfascial breast augmentation in four plastic surgery centers, from January 2008 to January 2010. The age of the patients ranged from 19 to 47 years, with a mean age of 31 years. All patients underwent breast augmentation because of small or hypoplasia of the breast. They were examined for the size of the breast, chest wall, and the condition of the skin of the breast. A careful patient-surgeon discussion was performed to choose the proper size of the breast implant. Standard preoperative and one year postoperative photographs were taken.

Preoperative marking for the boundaries of the pocket, the inframammary folds, and the midline of chest were drawn while the patient in the standing position. All patients were operated under general anesthesia. The procedure was carried out in the supine position with the arms abducted 90°.

Inframammary approach was used in 84 patients and inferior periareolar incision in the other 16 patients. One gram of third generation cephalosporin was given intravenous at the start of the surgery. Textured silicone gel-filled mammary implants with high or very high profile were used. The size of the breast implants ranged from 280 to 375cc.

#### *Surgical technique:*

The pocket and the proposed incision line were infiltrated with 200cc normal saline mixed with 1cc epinephrine 1%. With the inframammary approach, a 4-cm incision was made within the inframammary fold centered on a vertical line crossing the areola. The dissection was carried out through the subcutaneous tissue reaching to the pectoral fascia. The pectoral fascia was incised and with good visualization offered by the optic fiber illumination, the subfascial pocket was undermined by the electroscalpel connected to a fine Colorado needle. The undermining was carried out releasing the fascia from the pectoralis muscle. Undermining was stopped medially 2cm from the midsternal line. Because subfascial plane was a bloody plane, meticulous hemostasis was carried out. After completion of pocket dissection, a sizer was inserted to check the adequacy of the pocket and the suitability of the chosen size of breast implant. The implant was bathed in 500cc of normal saline mixed with 80gm gentamicin. The same solution was used to irrigate the pocket immediately before insertion of the implant. Gloves were changed before handling the implant. A final inspection under fibro-optic illumination was done to make sure that complete dissection and hemostasis of the pocket were achieved. The implant was inserted in the subfascial plane with the minimal manipulation. After insertion of both sides, the operating table was flexed 45° to allow the visualization of the breasts in the semi-sitting position. Immediate revision was made if any asymmetry or tethering was noticed. The wound was closed in layers; the pectoral fascia was separately sutured, followed by the subcutaneous tissue and skin.

With the periareolar approach, a lower circumferential incision was made and dissection through the breast parenchyma was carried out in a backward and downward directions. The dissection was continued to reach the pectoral fascia at the level of the inframammary fold. The pectoral fascia was incised and with the guidance of the fibro-optic retractors, the subfascial pocket was dissected. After insertion of the implant, meticulous wound

closure was carried out, including the deep parenchymal layer.

#### *Postoperative care:*

Immediately after breast augmentation, a push-up bra was worn for several weeks. Postoperative massage was allowed by the nurse or the patient's herself in horizontal and vertical directions. All patients were instructed not to sleep on the prone position.

## RESULTS

With a mean of one year follow-up period; retrospective analysis of the data of the patients from 4 different centers showed that 89 patients (89%) were satisfied with results (Figs. 1-5). The patients were satisfied with the shape of the breast, the projection, and the long term results. Two patients developed postoperative hematoma which required exploration of the wound, delivery of the implant and control of bleeding (Table 1). Three patients developed variable degrees of asymmetry; two of them were subjected to readjusting procedures without change the implants. Three patients developed bottoming-out six months postoperative. Several months postoperative; three patients were not satisfied with size of the breast and the implants were changed with different sizes. Pain for several days was the most annoying complaint in the early postoperative period. The surgeons compared the average postoperative time for pain feeling with this technique with the subglandular technique in another group. The average duration of pain feeling with subfascial plane was 5 days compared with 3 days with the subglandular plane.

## DISCUSSION

Surgeons have been seeking for the proper plane into which the implant might be placed. The authors first began breast augmentation with subglandular plane and experienced problems of implant contour palpability and visibility, rippling/wrinkling, capsular contracture, and bottoming out [1]. This is more evident in thin patients with less soft tissue coverage, in which a sharp transition can be seen in the upper pole.

Table (1): Postoperative complications.

Complications	Number of patients
Hematoma	2
Asymmetry	3
Bottoming-out	3

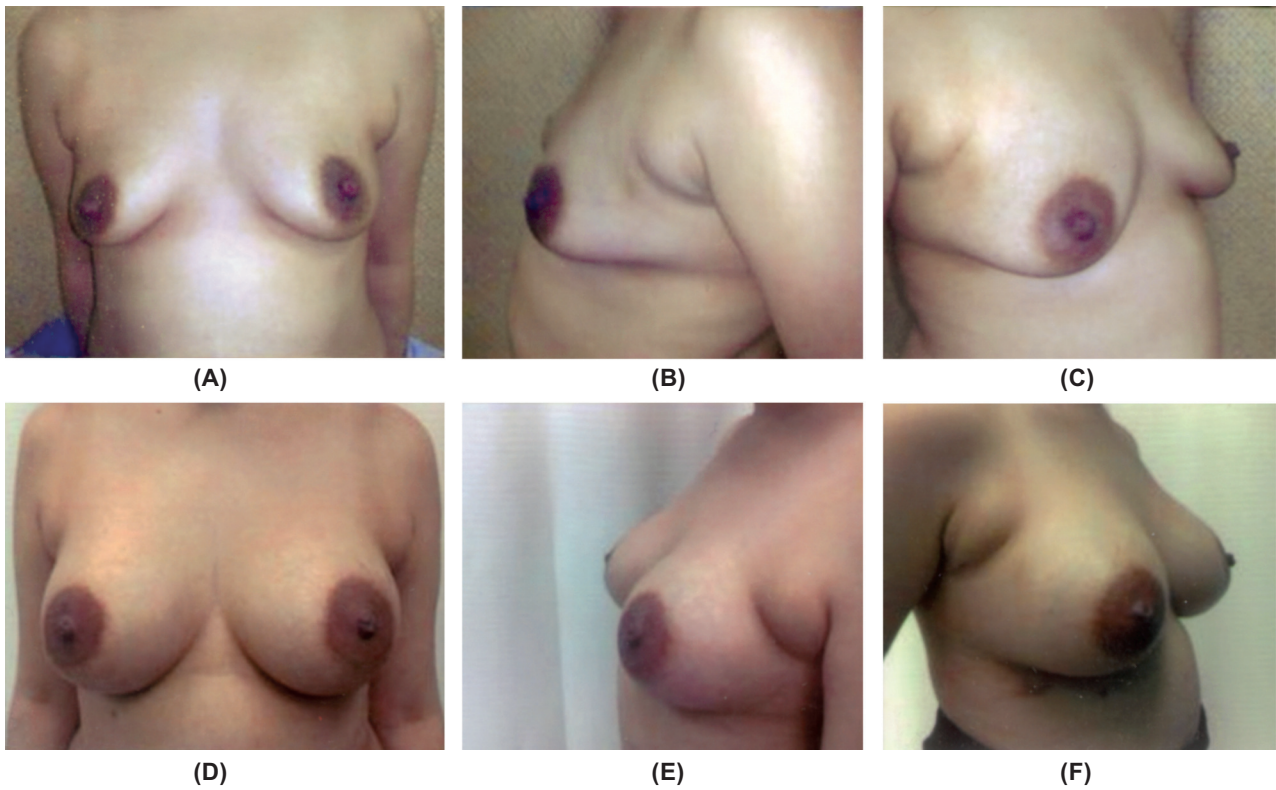


Fig. (1): (A,B,C) Preoperative front, lateral, and profile views of a 23-year old female patient with small breast. (D,E,F) One year postoperative views of the breast augmentation using 350cc silicon gel-filled mammary implant inserted in a subfascial plane.

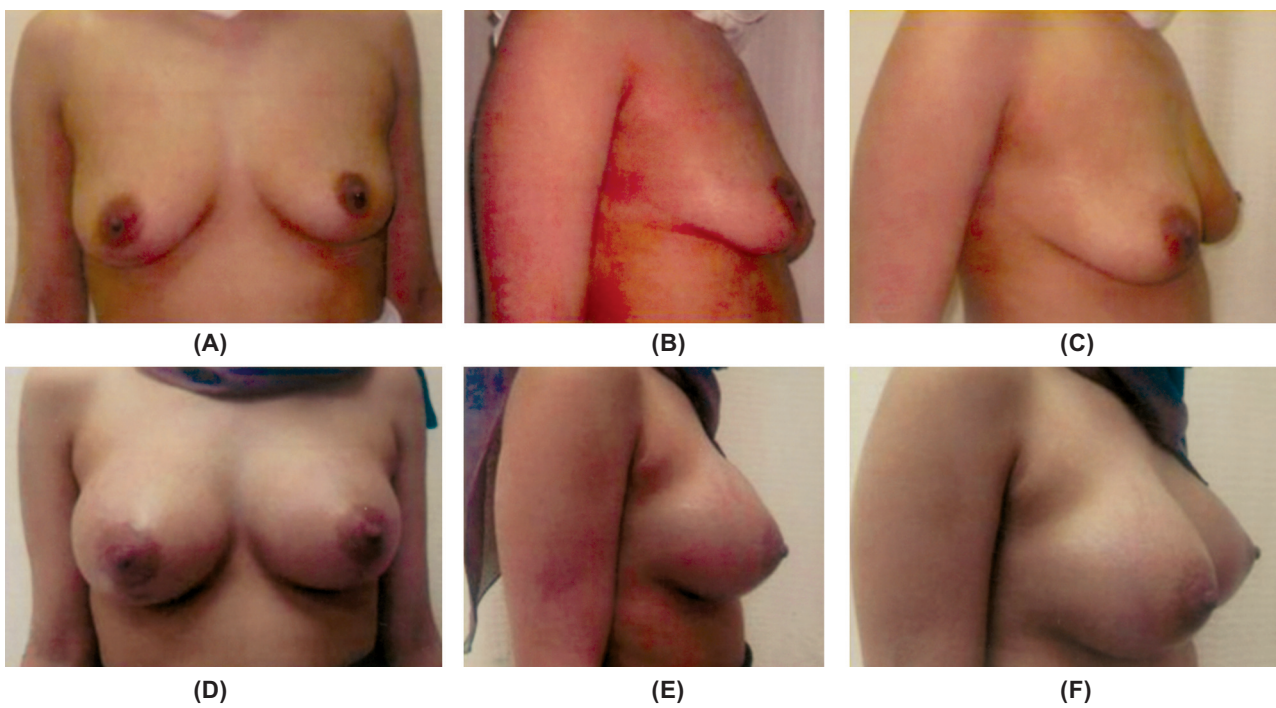


Fig. (2): (A,B,C) Preoperative front, lateral, and profile views of a 27-year old female patient with small breast. (D,E,F) One year postoperative views of the breast augmentation using 325cc silicon gel-filled mammary implant inserted in a subfascial plane.



Fig. (3): (A,B) Preoperative front and lateral views of a 22-year old female patient with hypoplasia of the breast. (C,D) One year postoperative views of the breast after augmentation with 280cc silicone gel-filled mammary implant inserted in a subfascial plane.

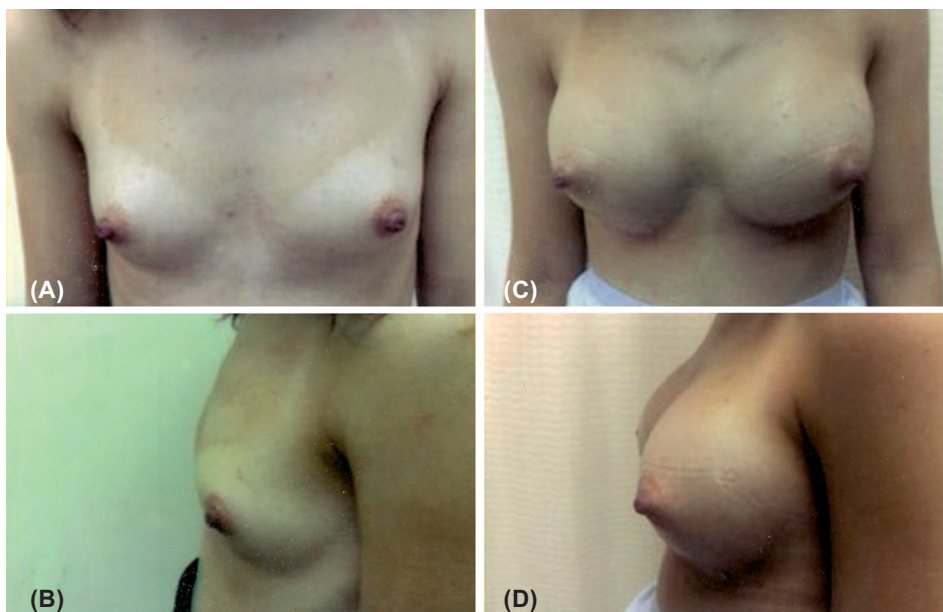


Fig. (4): (A,B) Preoperative front and lateral views of a 25-year old female patient with hypoplasia of the breast. (C,D) 10 months postoperative views of the breast after augmentation with 320cc silicone gel-filled mammary implant inserted in a subfascial plane.

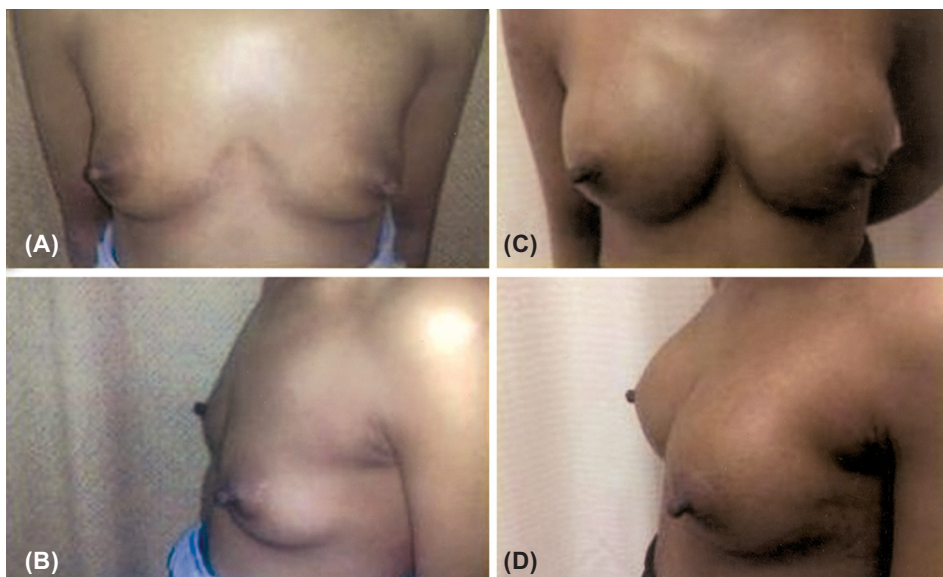
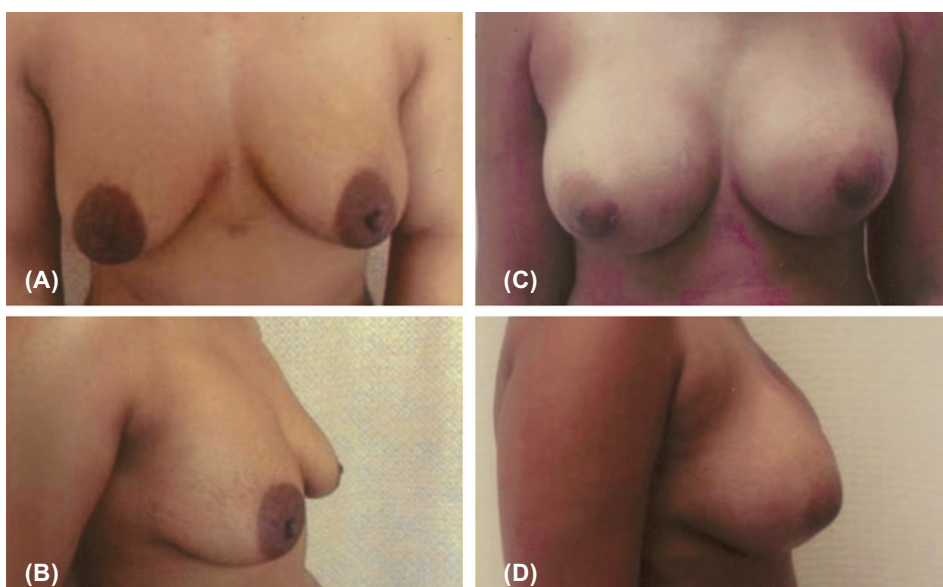


Fig. (5): (A,B) Preoperative front and lateral views of a 31-year old female patient with a small breast. (C,D) One year postoperative views of the breast after augmentation with 350cc silicon gel-filled mammary implant inserted in a subfascial plane through circumareolar approach.



With the objective of improving the aesthetic outcome, alternative options for implant pockets have been mentioned. The submuscular position was introduced to provide optimal implant coverage [8,12,13]. However, the main drawbacks with this approach are related to implant distortion, breast asymmetry, and postoperative pain [13,14,22]. However, Scott et al. reported that transecting the pectoralis major muscle seems to be excessively destructive; especially this maneuver may cause secondary problems such as a depression or thinning in the inferior pole, especially if the patient is very thin. The authors also reported that partial or complete coverage of the implant with the pectoralis muscle causes loss of the animation of the breast [23].

Dual-plane breast augmentation, introduced by Tebbetts [17], was developed to minimize the risk of implant contour deformity using the subpectoral plane associated with the subglandular plane. According to the author, the technique improves the implant-soft tissue relationship by adjusting the positions of the pectoralis muscle and glandular tissue relative to the implant. However, the technique did not offer the ideal implant/soft tissue dynamic. Furthermore, bottoming-out of the implant and marked postoperative pain from muscle splitting are the tradeoffs of the procedures [13,14,22].

The subfascial technique described by Graf and his colleagues is particularly attractive for surgeons who have been seeking alternative planes [19]. According to the authors, the pectoralis muscle fascia, a well-defined structure in the upper thorax, is useful for minimizing the appearance of the implant edges. One of the main advantages of subfascial breast augmentation is the creation of a stronger support system for the implant's superior pole. Implant displacement in the superior direction is avoided because the upper pole is placed between the muscle and the fascia, which constitutes a stronger support system than only the breast parenchyma and/or subcutaneous tissue in the conventional subglandular approach [2,24,25,26]. The implant remains securely in place and a natural outcome is enhanced because the skin and subcutaneous tissue in the upper third of the pocket are no directly in contact with the implant [19,20].

Subfascial breast augmentation possesses the advantages of the subglandular plane with the improvements that may be achieved by using the subpectoral approach, having more tissue available to cover the implant's upper pole. Although the fascia offers less tissue for coverage than the

pectoralis major muscle, some potential benefits of using the latter have been achieved; tradeoffs of the subpectoral approach such as the tendency for lateral and superior displacement or malposition over time, increased morbidity in terms of pain and recovery, less control over the inframammary fold's position have been significantly decreased [2,24-26].

The dissection of the pocket in the subfascial plane is more tedious and results in increased bleeding and longer operative time [2]. In this study, the average operation time was 75 minutes. Two patients (2%) developed postoperative bleeding which is not more than other planes. However, our experience proved that good hemostasis can be obtained using the electroscalpel for dissection and infiltration of the dissection area with diluted vasoconstrictive epinephrine.

#### *Conclusion:*

The subfascial breast augmentation technique offers improved long-term aesthetic results because of the better dynamics between the implant and the soft tissues. This technique is easy and can replace other conventional planes.

#### **REFERENCES**

- 1- Hidalgo D.A.: Breast augmentation: Choosing the optimal incision, implant, and pocket plane. *Plast. Reconstr. Surg.*, 105: 2202, 2000.
- 2- Siclovan H.R. and Jomah J.A.: Advantages and Outcomes in Subfascial Breast Augmentation: A Two-Year Review of Experience. *Aesth. Plast. Surg.*, 32: 426-431, 2008.
- 3- Cronin T. and Gerow F.: Augmentation mammoplasty: A new "natural feel" prosthesis. In: Broadbent T.R., ed. *Transactions of the Third International Congress of Plastic Surgery*. Amsterdam: Excerpta Medica Foundation, 1964.
- 4- De Cholnoky T.: Augmentation mammoplasty. Survey of complications in 10,941 patients by 265 surgeons. *Plast. Reconstr. Surg.*, 45 (6): 573-7, 1970.
- 5- Handel N., Jensen J.A., Black Q., et al.: The fate of breast implants: A critical analysis of complications and outcomes. *Plast. Reconstr. Surg.*, 96 (7): 1521-33, 1995.
- 6- Tarpila E., Ghassemifar R., Fagrell D. and Berggren A.: Capsular contracture with textured versus smooth saline-filled implants for breast augmentation: A prospective clinical study. *Plast. Reconstr. Surg.*, 99 (7): 1934-9, 1997.
- 7- Araco A., Gravante G., Araco F., Delogu D., Cervelli V. and Walgenbach K.: A retrospective analysis of 3,000 primary aesthetic breast augmentations: Postoperative complications and associated factors. *Aesthetic Plast. Surg.*, 31 (5): 532-9, 2007.
- 8- Jarrett J.R., Cutler R.G. and Teal D.F.: Subcutaneous mastectomy in small, large, or ptotic breasts with immediate submuscular placement of implants. *Plast. Reconstr. Surg.*, 62: 702-702, 1978.

- 9- Mahler D., Ben-Yakar J. and Hauben D.J.: The retropectoral route for breast augmentation. *Aesthetic Plast. Surg.*, 6 (4): 237-42, 1982.
- 10- Tebbetts J.B.: Transaxillary subpectoral augmentation mammoplasty: Long-term follow-up and refinements. *Plast. Reconstr. Surg.*, 74 (5): 636-49, 1984.
- 11- Matarasso A. and Hutchinson O.H.Z.: Augmentation mammoplasty: Subpectoral augmentation using the peri-areolar or inframammary approach. *Plast. Reconstr. Surg.*, 7: 93-99, 2000.
- 12- Davidson B.A.: Submuscular breast augmentation. *Aesth. Surg. J.*, 23: 293-299, 2003.
- 13- Codner M.A., Cohen A.T. and Hester T.R.: Complications in breast augmentation: Prevention and correction. *Clin. Plast. Surg.*, 28: 587-595, 2001.
- 14- Tebbetts J.B.: Alternatives and trade-offs in breast augmentation. *Clin. Plast. Surg.*, 28: 485-500, 2001.
- 15- Strasser E.J.: Results of subglandular versus subpectoral augmentation over time: One surgeon observations. *Aesth. Surg. J.*, 26: 45-50, 2006.
- 16- Hendricks H.: Complete Submuscular Breast Augmentation: 650 Cases Managed Using an Alternative Surgical Technique. *Aesth. Plast. Surg.*, 31: 147-153, 2007.
- 17- Tebbetts J.B.: Dual plane breast augmentation: Optimizing implant soft tissue relationships in a wide range of breast types. *Plast. Reconstr. Surg.*, 107: 1255-1272, 2001.
- 18- Spear S.L., Carter M.E. and Ganz J.: The correction of capsular contracture by conversion to 'dual-plane' positioning: Technique and outcomes. *Plast. Reconstr. Surg.*, 118: 103S-113S, 2006.
- 19- Graf R.M., Bernardes A., Rippel R., Araujo L.R.R., Costa Damasio R.C. and Auersvald A.: Subfascial breast implant: A new procedure. *Plast. Reconstr. Surg.*, 111: 904-908, 2003.
- 20- Sampaio Goes J.C. and Landecker A.: Optimizing outcomes in breast augmentation: Seven years experience with the subfascial plane. *Aesth. Plast. Surg.*, 27: 178-184, 2004.
- 21- Barbato C., Pena M., Triana C. and Zambrano M.A.: Augmentation mammoplasty using the retrofascia approach. *Aesth. Plast. Surg.*, 28: 148-152, 2004.
- 22- Spear S.L., Bulan E.J. and Venturi M.L.: Breast augmentation. *Plast. Reconstr. Surg.*, 114: 73, 2004.
- 23- Scott L. Spear, Jaime Schwartz and Joseph H. Dayan: Outcome assessment of breast distortion following Submuscular breast augmentation. *Aesth. Plast. Surg.*, 33: 44-48, 2009.
- 24- Goes J.C. and Landecker A.: Optimizing outcomes in breast augmentation: Seven years of experience with the subfascial plane. *Aesth. Plast. Surg.*, 27: 178, 2003.
- 25- Benito-Ruiz J.: Subfascial breast implant. *Plast. Reconstr. Surg.*, 113: 1088, 2004.
- 26- Serra-Renom J., Garrido M.F. and Yoon T.: Augmentation mammoplasty with anatomic soft, cohesive silicone implant using the transaxillary approach at a subfascial level with endoscopic assistance. *Plast. Reconstr. Surg.*, 116: 640, 2005.